

SureSmile® Advanced

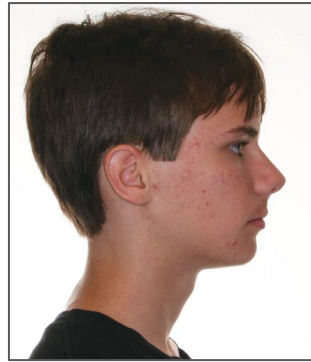Protocol for Therapeutic Photographs

Therapeutic Models require a set of standard photos (3 facial, 5 intraoral) taken within 4 weeks before or 2 weeks after the scan. The “full mouth” and “overjet” photos are strongly recommended. Required x-rays: a current panorex and a current or previously imported ceph.




Front

- Patient looking forward
- Head leveled, ears visible
- Lips together & relaxed
- Capture collarbone, top of head



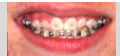Profile

- Hair behind ears
- Lips together & relaxed
- Patient looking forward
- Capture collarbone

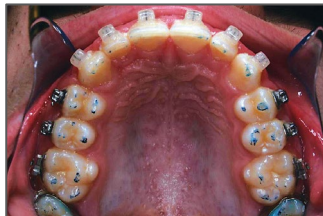

Smile

- Patient looking forward
- Head leveled, ears visible
- Patient's natural smile
- Capture collarbone, top of head

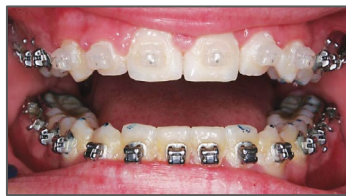

**submit additional photo if 3-3 not in view*



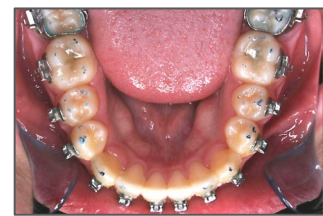Upper Occlusal

- Use articulating paper
- Take photo of reflection in mirror
- Rest mirror behind lower molars
- Capture all teeth including 2nd molars



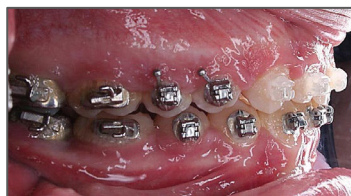Full Mouth (Optional)

- Slightly open to see incisal edges
- Capture 2nd molar to 2nd molar



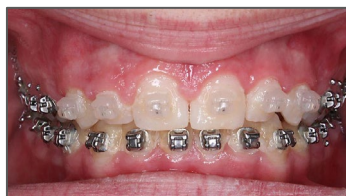Lower Occlusal

- Use articulating paper
- Take photo of reflection in mirror
- Retract tongue with mirror
- Rest mirror behind upper molars
- Capture all teeth including 2nd molars



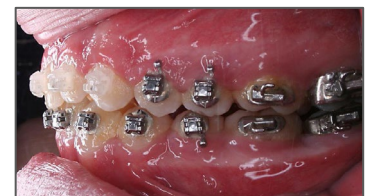Right Buccal

- Capture class relation of bite
- Straight shot of cuspid, bicuspid & molars
- Capture 1st cusp tip of 2nd molar
- Use buccal mirrors if necessary
- Place a colored “O” ring on one bracket



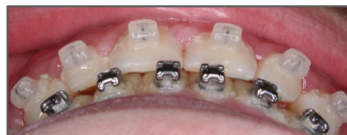Frontal

- Patient's true bite
- Parallel to occlusal plane & centered
- Capture 2nd molar to 2nd molar



Left Buccal

- Capture class relation of bite
- Straight shot of cuspid, bicuspid & molars
- Capture 1st cusp tip of 2nd molar
- Use buccal mirrors if necessary



Overjet (Optional)

- Capture bite 3-3 at 45° angle