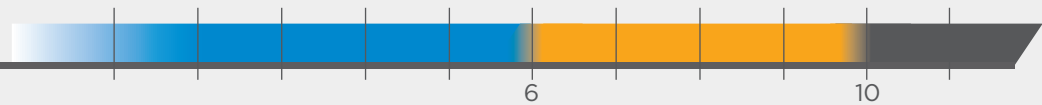
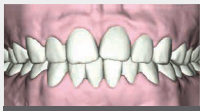

With experience, doctors can use SureSmile® Clear Aligners to treat a broad array of case types.

This guide is designed to help doctors confidently select appropriate cases for their experience level and treatment approach by offering clinical protocols with 3 levels of complexity ranging from easier (blue) to more complex (gray).

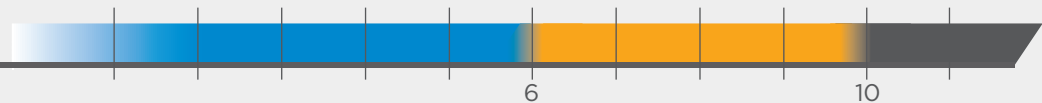
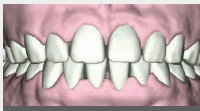The ranges below refer to the **amount of correction** desired in the treatment plan

Crowding



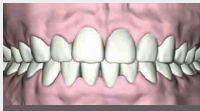Example: Level 1 includes correcting up to a maximum of 6 mm of crowding

Spacing



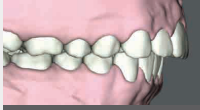Example: Level 1 includes correcting up to a maximum of 6 mm of spacing

Midline Deviation



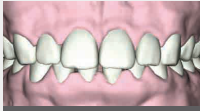Example: Level 1 includes moving a dental midline up to a maximum of +/- 1 mm

Overjet

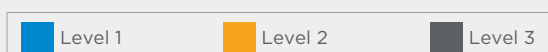

Example: Level 1 includes up to a maximum of +/- 2 mm of overjet correction

Overbite



Example: Level 1 includes up to a maximum of +/- 1 mm of overbite correction

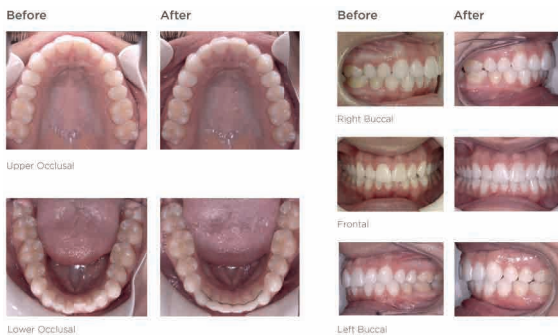

MILD
CASES

Crowding, Deep Bite

Age: 17 years old | Gender: Female
Treatment Duration: 4.25 Months U:8 L: 11
Treated for:

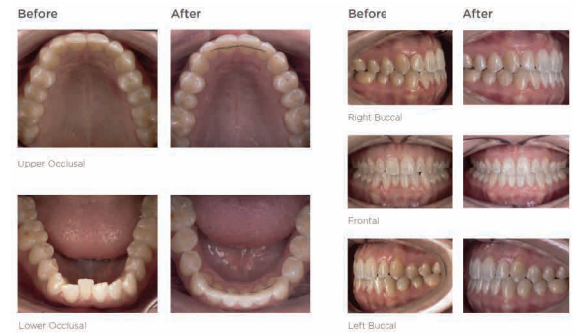- Slightly asymmetric MX and MD arches
- Mild MX crowding, moderate MD crowding
- Moderate deep bite with uneven incisal edges



Crowding, Shallow Overbite

Age: 27 years old | Gender: Female
Treatment Duration: 5 Months U:17 L: 17
Treated for:

- Moderate crowding lower incisors
- Shallow overbite

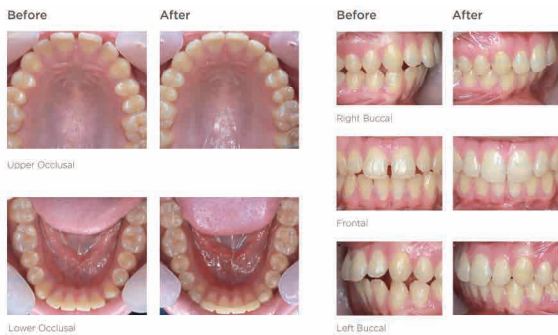

MODERATE
CASES

Spacing, Open Bite

Age: 16 years old | Gender: Male
Treatment Duration: 7 Months U:24 L: 16
Treated for:

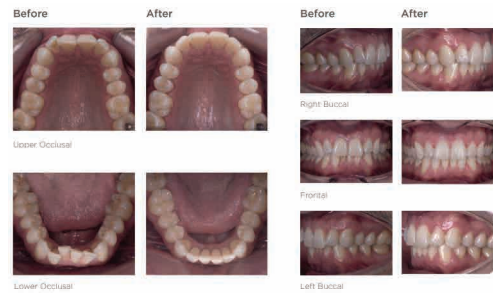- Mild maxillary transverse deficiency (3.45 mm)
- Central incisor protrusion



Crowding

Age: 41 years old | Gender: Male
Treatment Duration: 8.5 Months U:34 L: 32
Treated for:

- Upper and lower arch with moderate crowding
- Moderate deep overbite
- Lack of labial crown torque of upper central incisors
- Mild to moderate generalized gingival recession, specifically on the area of lower incisors

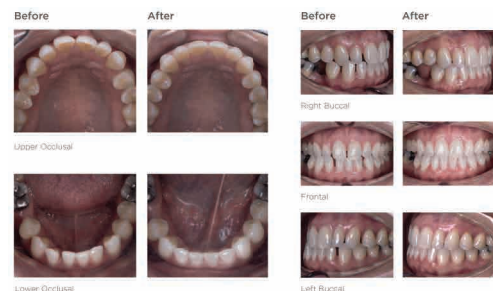

SEVERE
CASES

Anterior Crossbite, Spacing

Age: 34 years old | Gender: Female
Treatment Duration: 10.5 Months U:41 L: 33
Treated for:

- Mild Class III
- Moderate spacing upper and lower arch
- Midlines off 1.5 mm
- Crossbite upper right lateral incisor and canine
- Missing lower right 2nd bicuspid



Crowding

Age: 40 years old | Gender: Male
Treatment Duration: 11.5 Months U:46 L: 41
Treated for:

- Mild class III
- Minor to moderate crowding
- CO/CR discrepancy due to primary posterior contact
- 1mm open bite of the right canines and left lateral incisors

